



Homœopathy on the move

Strategies, Healing, Similitudinum, Sanae

48th Congress of
Liga Medicorum
Homoeopathica Internationalis

→ 16/19, July 2014

Palais des Congrès - Paris, France




Case reports of Acne with long lasting follow up.

Chatzimanuil A. DDS Secretary

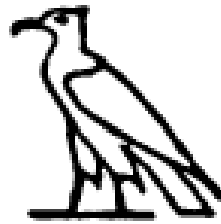
Dernikou M.F. MD, MSc Homeopathy.

Tsilikas A.MD, Dermatologist, MSc Homeopathy, board member

Michalakis M. DDS, MSc, specialist in Oral Diagnostics&Radiology,President.

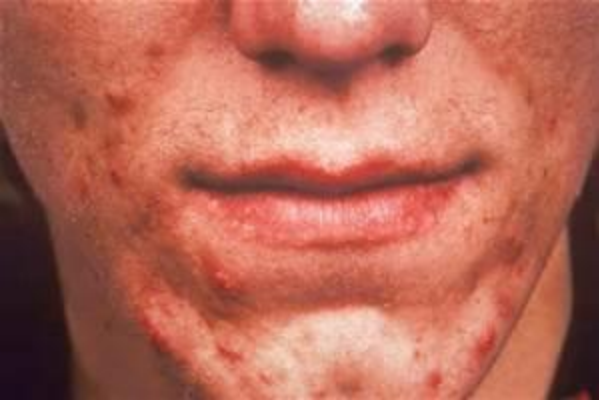

aku-t

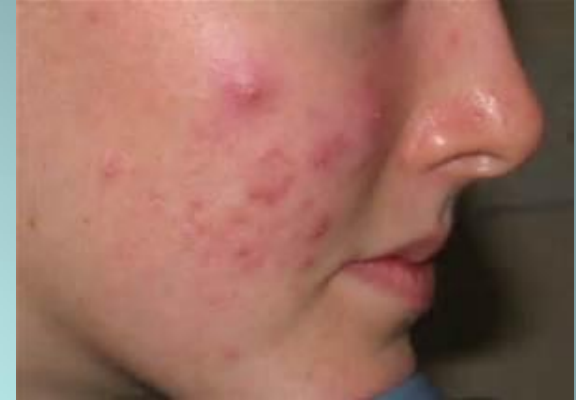

- The word "aku-t" occurs in the **Ebers Papyrus**⁶ and elsewhere and is translated⁵ as "boils, blains, sores, pustules, any inflamed swelling". The meaning of the Greek word "**AKMH**" is important. Previous to the second century A.D. it had a definite medical meaning, to which Galen⁵ devotes a whole paragraph, as "the height of a disease", "the crisis of a fever", and is not in any way related to skin disease. However, in the second century A.D. its meaning appears to be widened to include the **height or culmination of growth** and **peak development** and thus "puberty". It is in this meaning that it first appears in relation to «IONΘOI» in the works of the Greek physician Julius Pollux. The Latin text is not infrequently quoted in later literature but the Greek text seems more significant philologically

- Some think of acne as a modern phenomenon. But quite the contrary, ancient people wrote of acne as soon as they could write at all. Ancient Egyptian writings mention how **Pharaohs** struggled with the disease. Traces of an essential oil used in the treatment of acne scars were found in King Tut's tomb.
- The ancient Greek physicians certainly recognized acne which they knew as **IONΘOI**, a condition which Aristotle¹ describes in sufficient detail for there to be little doubt of the identification. Hippocrates² also uses the term, but does not state what he means by it, although his wording suggests that it was a well-known and recognized disease. **That Acne were associated with puberty is implied** in the meaning of this word in the singular, IONΘΟΣ, which means "**the first growth of the beard**". The early Roman physicians, on the other hand, used the word "**varus**" which is mentioned by Pliny³ and discussed briefly by Celsus⁴.



Acne vulgaris

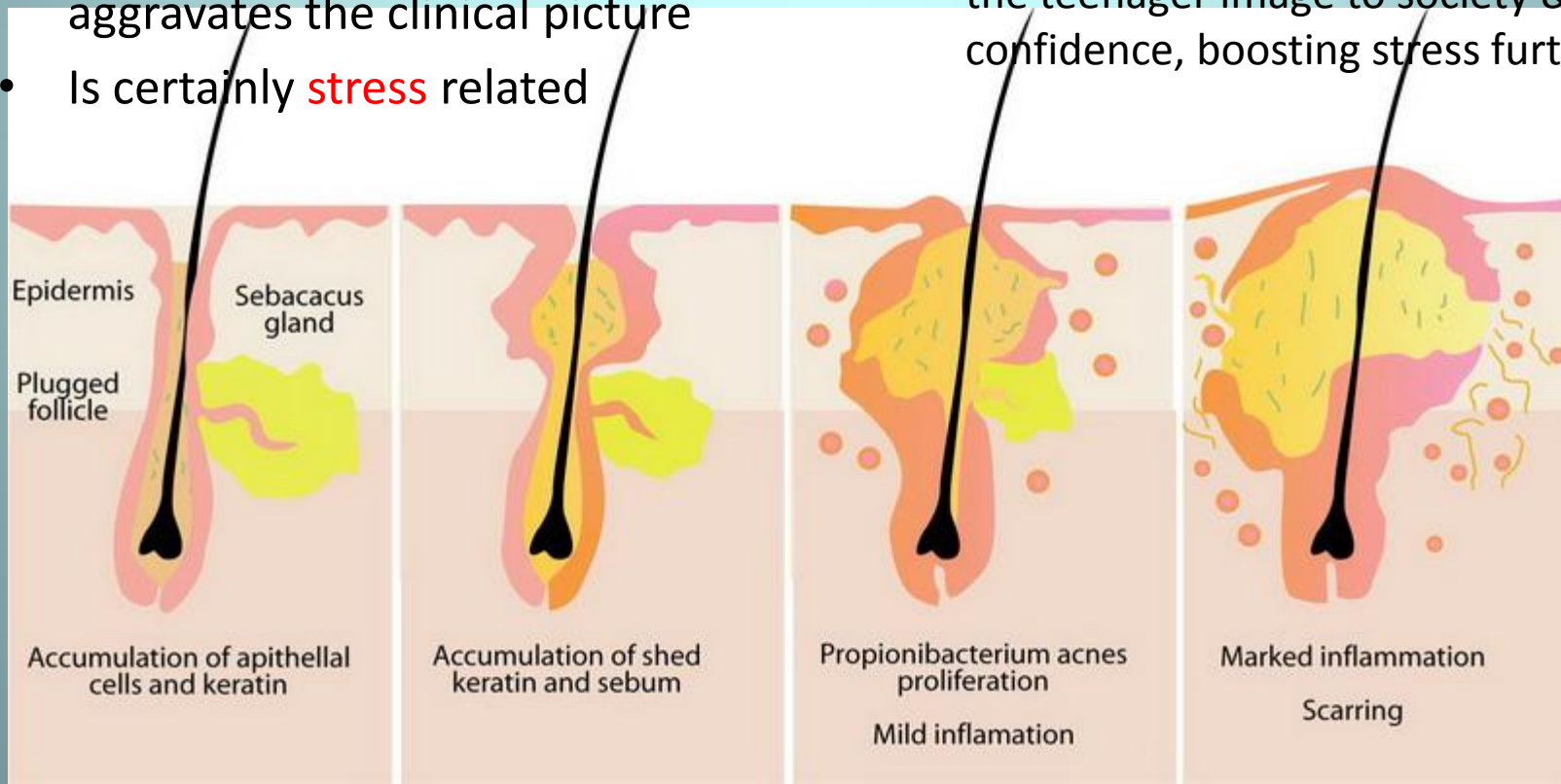


blackheads (comedones), inflamed pustules and papules (pimples) and whiteheads (closed comedones). Acne vulgaris **usually affects the face** but can show up on the **ears, neck, chest and back**. This occurs because these areas contain **more sebaceous glands** than other areas of the body.

- Is a chronic inflammatory disease
- Appears most common in adolescence especially and around it.
- It affects about 80% of persons in this age group.
- Can be accompanied with various skin problems of early and late youth mostly related to the level of **variability in hormones** primary androgens.

Particular acne is of multifactorial pathogenesis:

- **Androgens** stimulate hyper production of sebum
- excessive sebum **blocks** the pilosebaceous units which are hyper-keratinized and **infected** with **Propionibacterium** acnes.
- Excess Uptake in **carbohydrates** aggravates the clinical picture
- Is certainly **stress** related
- the **skin** represents the outer lever of the human core (where probably the vital force exists⁹) but as an organ it seems to affect greatly future resistance to **physical and psychic** stress of a human being.
- Unfortunately this chronic inflammatory disease affects greatly the teenager image to society & self confidence, boosting stress further ..



Current Acne treatments:

Systemic :

Antibiotics:

Minocycline

***Tetracycline*^{1,2}**

***Doxycycline*¹**

Benzoyl Peroxide

azelaic acid

retinoic acid (tretinoin,
adapalene, tazarotene)

birth control pills (females)

***Isotretinoin*(Accutane)¹**

Local:

- **Chemical peelings :**
- **Mechanical peelings-Microdermabrasion:**
Scrubs Abrasive pads and cloths

- **Laser**

- **Phototherapy:** ¹⁰can be used to treat mild to moderate acne only

When porphyrins are exposed to wavelength **blue-violet** light from 405 to 420 nanometers, oxygen is separated from the porphyrin molecule producing free radicals which kills the bacteria.

RED Light Therapy 655nm-665nm exhibits Anti-Inflammatory Action – reduces the redness and inflammation associated with acne lesions.

Promotes wound healing and tissue growth – this action is beneficial for acne scars which is common with moderate and severe acne.

1st case Female **18Y** H:168cm,W:54Kg⁽¹⁹⁹⁴⁾

- Acne symptoms were painful located in the chin, cheeks, chest, back
- The skin condition affected her self-confidence, felt shy
- 19-20 Y old⁽¹⁹⁹⁵⁻⁹⁶⁾, Prescribed: Minocin (**tetracycline**) for 2 months, Vibramycin (**doxycycline**)
- Accutane 10mg (**isotretinoin**) for 4 months^{1997-21Y old}

Post treatment ¹⁹⁹⁷ changes took place:

- Was happy after treatment since skin condition was overall improved.
- Very irritable, screaming, fighting
- **Dry lips & burning sensation**
- **Dry skin & itching**
- **Knee pain (L)**

- **Isotretinoin:** was originally recommended for people with severe acne that did not respond to other treatments '**nuclear option**' for acne
- Exactly how Accutane works on a cellular level **is unknown** but we do know that it affects all four ways that acne develops.
 1. It dramatically reduces the size of the skin's **oil glands** (35%-58%) and even more dramatically reduces the amount of oil these glands produce (around 80%).⁸⁻⁹
 2. Acne **bacteria** (*P. acnes*) live in skin oil. Since oil is dramatically reduced, so is the amount of acne bacteria in the skin.⁹
 3. It slows down how fast the skin produces **skin cells** inside the pore, which helps pores from becoming clogged in the first place.¹⁰
 4. It has **anti-inflammatory** properties.¹⁰

Side effects 1st case

Isotretinoin *More common:*

Bone or joint pain+++
changes in behavior+
mental depression ++
aggression or agitation.
difficulty moving+
dryness of the lips+
cracking or peeling skin
itching++
tiredness, weakness+

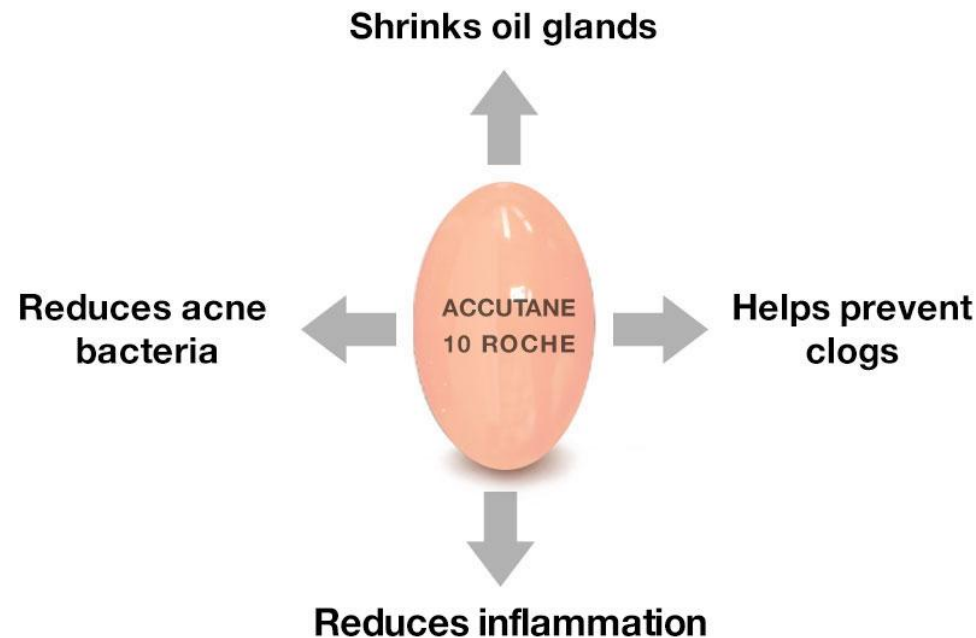
This is not a complete list of the side effects.

Remark: Isotretinoin action on a cellular level is unknown

epigenic impact is of concern¹³

aku-t

Cure rate = 66%



2Y later.. Knee pain accompanied with acne¹⁹⁹⁹

1st Homeopathic Doctor:¹⁹⁹⁹⁻²⁰⁰⁸

Remedies: Silica, **Ign**, Nat-m, Ars, **Phos**, Borax, **Calc-c**, Bry, Coloc, China, Gels, Hep, Ip, Kali-bi, Nux-v, Puls, Sep, Rhus-t, Sulp, **Calc-c**, **Phos**, Cocculus.
23-28Y Acne reappeared under intense stress.

2nd Homeopathic Doctor:²⁰⁰⁸⁻²⁰¹⁰

5-08 **Calc-c** 200ch, 1M Anxiety-weakness
12-08 Natr-m 200ch, 1M Herpes, Acne
31-12-08 Sulp 30ch/4 Acute skin rashes
01-09 Arnica 200/3 back-injury (+nimesulid)
3-2010 Ars30ch/4 (Ign?) GIT&Anxiety

3rd Homeopathic Doctor²⁰⁰⁹⁻²⁰¹⁴

33Y Tarentula 10M Skin reaction²⁰⁰⁹

Acne facial resolved 34Y²⁰¹⁰

Recurrent Vaginal Candidiasis since 2010

Itching ²⁰¹³. R: Antifungal treatment per Os for candidiasis, Phos main Homeop Remedy 2010-2013

Severe Left Hip pain²⁰¹² (she links with candidiasis)

R: conventional medication and painkillers. Hip joint replacement proposed!

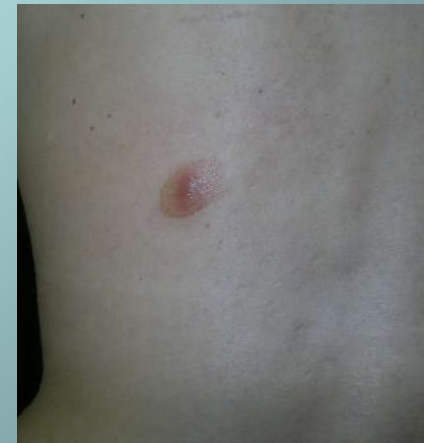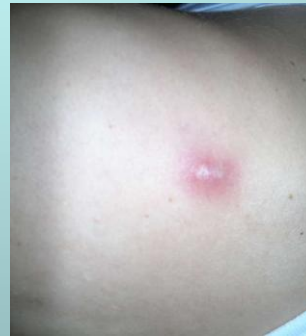7-2013 Phosp 1M/3 Anxiety,

10-13 Phos 1M, 11-13 Phos 10M,

11-13 Sepia

1-14 **Ign 1M** (reaction-pict.)

3-14 Ars..




1st case evaluation

Acne is no more present

- High creativity
- Mild-moderate scarring
- Muscle-skeletal recurrent complains (algias)
 - Sensitive to stress
 - Grief-conflicts
 - Anxiety & fears

Palliative Homeopathic treatment



2nd case: Male 16Y, 172cm W:62kg (1984)

- **Treated for conjunctivitis** 4-7-1984 with Maxitrol (neomycin and polymyxin B sulfates and dexamethasone)
- Acne onset
- 9-8-1984 administered tetracyclines and locally with Fenistil (Dimetindene maleate) & Retavate cream (Adrenal cortical steroids, Glucocorticoids)
- 9-1984 Treatment was non rewarding the efforts thus switched to Homeopathy and complementary dermatology.

Homeopathy + nutrition

- **Nutrition was modified banning most beverages and sugar.**
- The skin condition included large staphylococcus papules in the face accompanied with itching and soreness
- The homeopathic treatment for Acne supported the nutritional modification and the **remedy fitted** both constitutional and local symptomatology.
- The **skin pathology cleared with the first prescription and non-scarring** remained
- Homeopathy was chosen as main course of treatment until today. ²⁰¹⁴

Side effects (drugs.com) 2nd case

Neomycin-(less serious):

- mild nausea, vomiting
- mild diarrhea.

polymyxin B Incidence not known Dizziness

- Drowsiness, fever, **headache, stiff neck**
- numbness or tingling in hands or feet, pain in the lower back or side, shakiness and unsteady walk, unsteadiness, trembling, or other problems with muscle control or coordination

Dexamethasone- *More common*

- Aggression, agitation, anxiety, blurred vision
- decrease in the amount of urine
- **Dizziness- headache-mood changes**
- Irritability, mental depression, Nervousness, fast, slow, pounding, or irregular heartbeat or pulse
- noisy, rattling breathing, numbness or tingling in the arms or legs, pounding in the ears, shortness of breath, swelling of the fingers, hands, feet, or lower legs, trouble thinking, speaking, or walking, troubled breathing at rest, weight gain

Incidence not known:

- **diarrhea-vomiting**


Tetracycline:

- **severe headache, dizziness**, blurred vision;
- fever, **chills**, body aches, flu symptoms;
- severe blistering, peeling, and red skin rash;
- urinating less than usual or not at all;
- pale or yellowed skin, dark colored urine, fever, confusion or **weakness**
- severe pain in your upper stomach spreading to your back, **nausea and vomiting**, fast heart rate;
- **loss of appetite**, jaundice (yellowing of the skin or eyes); or easy bruising or bleeding, unusual weakness.
- Less serious tetracycline side effects may include:
- sores or swelling in your rectal or genital area;
- mild nausea, vomiting, diarrhea, or stomach upset;
- white patches or sores inside your mouth or on your lips;
- swollen tongue, trouble swallowing; or
- vaginal itching or discharge.
- **This is not a complete list of side effects and others may occur....**

Patient History

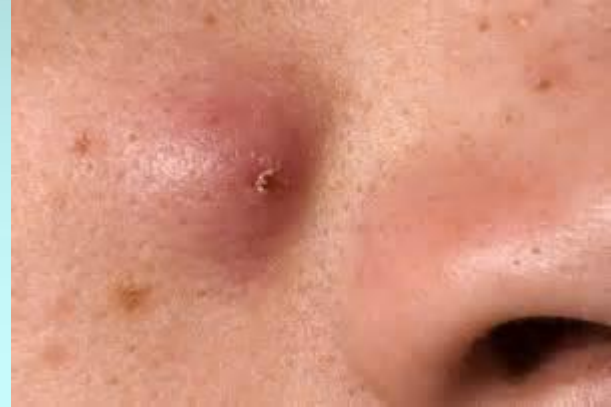Patient declares that he was feeling very ugly, being rude, acne was partially relieved bathing in the sea.

Post treatment (1984-1986) changes took place:

- became better student
- less desire for sugar
- **No- scar**  more social, self-confidence
- began to train
- acquired a more positive & creative attitude in life since.

Treatment details

- 1st Homeopathic Doctor
- 12-1984 Sulph 1M, 12ch/30caps (Acne) ↑↑
- 05-1986 >> 12ch/10 nose obstruction
- 02-1987 >> 200ch, 12ch/30
- 01-1992 >> 12ch/30
- 02-1993 Gels 200ch,6x/10 - Ign200ch (cold)
- 10-1993 Puls 200ch,6x/30
- 03-1994 Nat-M 200ch,1M,6x/30
- 07-1994 Arn 200ch, 12ch/10
- 2nd Hom.Doctor
- 06-1995 Puls 200ch,50M (sore abdomen&sadness) ↑↑
- 07-2003 Sulphur 200ch,1M,6x/30



- Ancient scholars have uncovered evidence of **sulfur** and mineral water treatments in ancient Rome .
As far as historians can tell, sulfur, despite its questionable efficacy, was the most popular acne treatment used in antiquity, all the way up until the 20th century when a bevy of other treatments started to hit the scene.

2003-2014

- 3-2005 Sulphur 1M weakness
- 9-2005 >> 1M,10M
- 2005 Merc-s 200ch apthae ulcers
- 2005 Ars 1M

Migrains & GIT-disorders (multi-prescribers)^{20Y}

- 10-2005 ARS 200ch
- 9-2006 >> Nausea, **Vomiting, Diarrhea**
- 10-2006 Sulph 200ch,1M,10M
- 10-2006 Phos 200ch GIT+**Anxiety**
- 12-2006 ARS 1Mx4
- 8-2007 ARS 200ch
- 6-2008 Sang 200ch,1M
- 9-2008 Ars 200ch
- 1-2009 Sang 200ch,30ch

02-2009 ARS 200ch

03-2009 Sang 30ch

03-2009 Bell 200ch,1M

03-2009 Staph 1M

04-2009 Nux-V 200chPuls, Nat-m, Ver-A, Ign, Phos..2011

9-2012 Arg-N 200ch,1M

12-2012 Ign 200ch

2-2013 Nat-m 1M

3-2013 Bry 200ch,1M cough suffocative

2-2014 Lyc 1M pain temples on cough-mild fever 38,5

1-4-2014 >> 10M (coffe)

18-6-2014 Sulp 200,1M tooth pain&back pain

Evaluation 2nd case

- No tissue scaring
- Creativity
- Achieved Emotional-
mental-physical
Homeostasis
- Impulsiveness
- Bone fractures



Top Homeopathic Remedies for Acne

Kent **Bold/50 Remedies:** Aurum, Calc-S, Cal-sil, Carb-an, Carb-v, Carbn-s, Caust, **Hep**, Kali-b, **Lyc**, Graph, Nux-v, **Sep**, Sil, Syph, **Sulp**.

Top-3.

The 'magic medicine' in homeopathy that helped me clear of my acne was **Sulphur** !

Pulsatilla: Young Girls Suffering from Acne with **menstrual difficulties**

Hepar sulphur: cases of acne, pustular in nature & white heads with pus points.

More rare:

- -**Arnica Montana**. With marked facial bruises
- -**Sulphur iodatum**- Acne in forehead and back
- **Natrium muriaticum**
- **Selenium**
- **Thuja**
- **Kalium bromatum** .

- -**Antimonium Tartaricum**- brunish scars
- -**Graphites**
- -**Lycopodium:** skin rushes & Git disordres
- -**Nux Vomica**- uses stimulants and medication
- -**Pulsatilla**- bluish color on rushes
- -**Sepia**- irritability
- -**Psorinum**- elderly

inflamed :

- -**Hepar sulphur** -acne rushes sensitive to touch.
- -**Calcarea Sulphurica**-short periods of acne.
- -**Calcarea Phosphorica**-weakness in youths

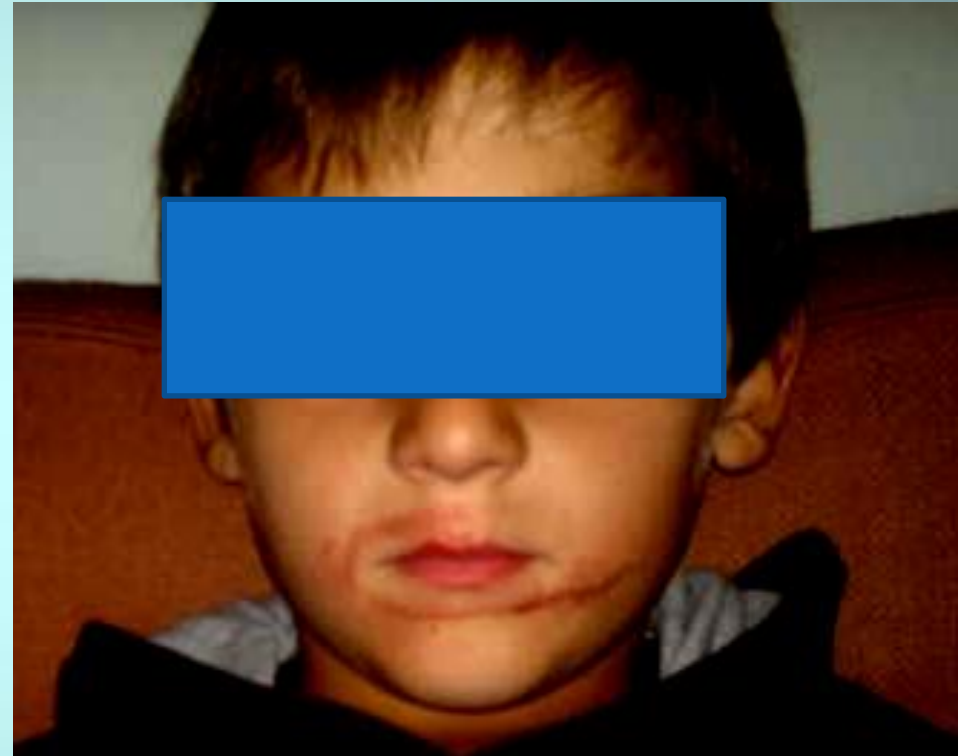Face –eruption- mouth around 1-2014 male 12Y (initially suppressed with cortisteroids for 6 months)

- Kent: Ant-t, Ars, Graph, Kali-chl, Kreo, Nat-ar, Nat-c, **Nat-m**, Nit-ac, Rhus-t, Sep, Staph, Sulp.

℞ :Puls 1M/10M

Result: in two days clear

Individualization!

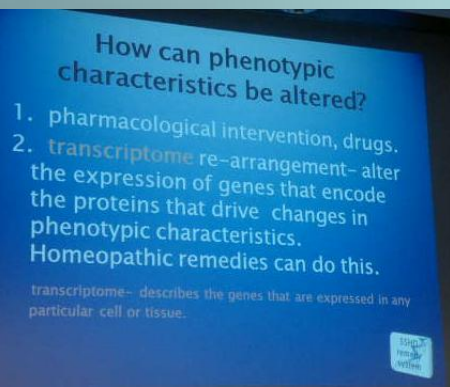


Homeopathy friendly local treatments

| substance | Action | Unblock pores Vit-c,salicylic & alphahydroxy Acids | Reducing inflammation | Removing sebum from skin | Side effects |
|---------------------|--|---|-----------------------|--------------------------|--|
| Soaps&lotion | Inhibit bacterial growth(ph:7-8) | | | Y | Parabens compounds |
| Vit-c(ph:3,5) | Anti-oxidant Collagen synthesis | Y | Inhibits NFkB | | Stinging,erythema Dryness observed |
| Alpha hydroxy Acids | Collagen synthesis Increase Dermal Perfusion | Y | N | | |
| Salicylic Acid | Exfoliates,penetrates the Follicle | Keep pores clear of Debris | N | | Mild dryness |
| Cosmetology Clays | Green for oily and Acneic skins, White :children and sensitive skins | | Y | | |
| Propolis tinct. | bactericidal | | Y | | |

Observations

- Acne vulgaris appears mostly in adolescence, due to the fact that the primary change in that age is hormonal outbreak and onset of human interrelationships.
- Conventional **medication Load** (complexity intensity & duration) will have an **epigenic effect**
- Any treatment or suppression will affect the health homeostasis in a long term base .
- Such a suppression limits an individual well being and happiness.
- Acne can be resolved both with conventional or complementary medicine
- Classical homeopathy provides permanent cure with no scarring or relapse.
- *Appropriate responsiveness of the human stress system to stressors is a crucial prerequisite for a sense of wellbeing, adequate performance of tasks, and positive social interactions, and hence for the survival of the self and the species. By contrast, inappropriate, over or under - responsiveness of the stress system may impair growth and development, and may account for the many chronic behavioral, endocrine, metabolic, and autoimmune disorders that plague contemporary humanity. **Prenatal life, infancy, childhood and adolescence are critical periods characterized by great plasticity and increased vulnerability to stressors**, in which **homeostatic mediators exert major organizational epigenetic effects. The genetic vulnerabilities leading to contemporary chronic diseases resulted from selective pressures of evolutionary stressors upon the genome during human phylogeny.**⁷*



Conclusion

This survey points out that there is ***delayed response*** to common medication for acne. In three years time for the first case, there was a relapse in pathology that was followed with left lower joint pain. Second case had migrains & GIT-disorders 20 years later. Epigenetic science that refers to a change in the expression of a gene, rather than in the actual base combinations (Dworkin, 2009) . **Drugs may alter epigenetic homeostasis** by direct or indirect^{13&1st case} mechanisms. It becomes increasingly apparent that chemicals(common pharmaceuticals) can cause changes in gene expression that persist long after exposure has ceased.¹² There is a need for further investigation to understand the mechanisms. Homeopathy has shown its efficiency treating acne especially in puberty ,conventional medication has to be used for treatment with acne with skepticism.

REFERENCES

- 1 ARISTOTLE. *Historia Animalium*, 556b, 29; *Problemata*, 36, 3; in Ed. Casaubon (1605) pp. 654B, 639E.
- 2 HIPPOCRATES. *De Morbis Vulgaribus*; in Loeb Classical Library, Hippocrates, 1, 188. *De Internus Affectionibus*; in Ed. Kuhn (1826) *Medicorum Graecorum Opera*, 22, 427.
- 3 PLINY. *Historia Naturalis*, Lib. 23; in Ed. Mayhoff, Lipsiae (1897) 4, pp. 7, 8, 27, 28.
- 4 CELSUS. *De Medicina*, Lib. 6, Cap. 5; Lugduni (1592) p. 552; Lee, London (1831) p. 136.
- 5. BUDGE, E. A. W. (1920) *An Egyptian Hieroglyphic Dictionary*. London; p. 11.
- 6. EBERS PAPYRUS. Tafel 71, line 21 and glossary; Engleman, Leipzig (1875).
- 7. Effects of science and technology on nature and environment: Genes, Brain, Stress and Evolution *GP Chrousos(Ann Clin Paediatr 2009, 56(4):555-558)*
- 8. Am Fam Physician. 2001 Dec 1;64(11):1873-8. Psycho dermatology: the mind and skin connection. Koo J¹, Lebowitz A.
- 9. Aegean Univ Msc paper in Holistic approach Psycho dermatology (Ολιστική προσέγγιση της Ψυχοδερματολογίας με Κλασσικά, Ψυχοδυναμικά και Εναλλακτικά Μοντέλα). Anastasios Tsilikas MD
- 10. P. Papageorgiou, A. Katsambas, A. Chu (2000) Phototherapy with blue (415 nm) and red (660 nm) light in the treatment of acne vulgaris *British Journal of Dermatology* 142 (5), 973–978.
- 11. Antibacterial properties of propolis . J M Grange and R W Davey. *J R Soc Med*. Mar 1990; 83(3): 159–160.
- 12. Epigenetic side-effects of common pharmaceuticals: a potential new field in medicine and pharmacology. Csoka AB¹, Szyf M. 2009 Nov;73(5):770-80. 2008.10.039. Epub 2009 Jun 5.
- 13. Temporal changes in gene expression in the skin of patients treated with isotretinoin provide insight into its mechanism of action. Amanda M Nelson, Wei Zhao,[†] Kathryn L Gilliland, Andrea L Zaenglein, Wenlei Liu,[‡] and Diane M Thiboutot. *Dermatoendocrinol*. 2009 May-Jun; 1(3): 177–187.

THANK U

